

From Our Office to Yours...

Our patients present with multiple dental conditions which clinicians must resolve in order to restore them to health.

These conditions may be treated with restorative or implant dentistry, or both, in combination with periodontal therapy.

There are many concepts which must be adhered to in an effort to produce predictable outcomes.

Excellent restorative and implant dentistry is the result of careful attention to many concepts which affect a predictable outcome.

*This current issue of **The PerioDontaLetter** addresses five concepts in restorative and implant dentistry important to achieving the long-term health and esthetic outcomes that we and our patients desire.*

As always, we welcome your suggestions and comments.

Five Suggestions to Facilitate Predictable Restorative Care

Important Elements in Functional Crown Lengthening

Functional crown lengthening is required when a tooth is badly worn, decayed or fractured too close to the gingival margin to facilitate an adequate restorative margin without violating the supracrestal tissue attachment (also known as the biologic width).

Supracrestal tissue attachment is the necessary space that must remain

between a restoration margin and crestal alveolar bone to permit a healthy, sustainable periodontal attachment. The ideal zone is approximately 2-3mm, but can vary based on location. Restorative margins which impinge upon the attachment may result in perceptible patient discomfort and chronic inflammation which may lead to localized periodontal bone loss.

Sufficient crown length facilitates periodontal health by improving access for preparation, isolation and impressions. This, in turn produces

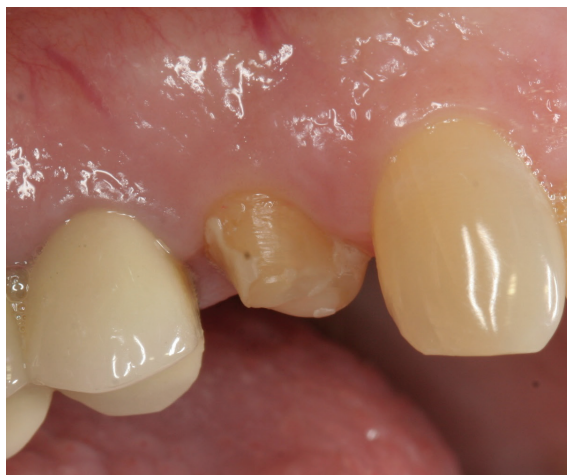
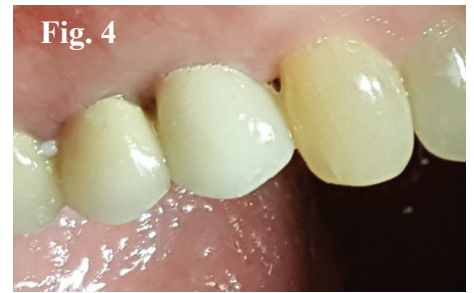
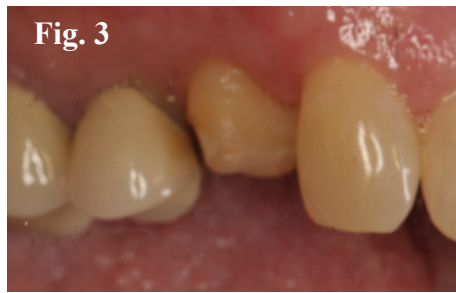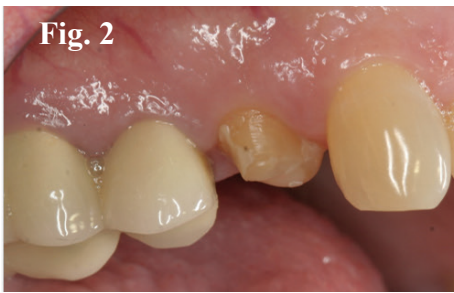Figure 1. A permanent restoration came off twice due to a short clinical crown which lacked sufficient tooth anatomy for retention. (See Figures 2, 3, 4 on page 2.)



Figures 2 and 3. Pre- and post- functional crown lengthening created sufficient crown length to retain a new restoration. Figure 4. The final crown has been retained without problems.

restorations that are long lasting and easy to maintain.

Functional crown lengthening surgically repositions the height of gingiva and crestal bone levels exposing sufficient sound tooth structure, referred to as the ferrule, to facilitate adequate preparation and final restorations which support long-term periodontal health. An adequate healing period is necessary before final restoration(s) in order to allow the complete maturation of the healing tissues.

Periodontal status, biomechanics, occlusion and esthetics are important

factors to be considered prior to crown lengthening.

- The periodontium should be free of periodontal disease.
- Overall restorability of the tooth should be considered prior to crown lengthening. Caries removal and endodontic therapy should also be considered prior to treatment to ensure there are no unexpected findings.
- When operating in the esthetic zone, caution must be exercised to avoid inter-proximal crestal bone reduction which may result in the loss of the

interproximal papilla creating unsightly spaces. Following the normal scallop of the tissues will help avoid one tooth appearing longer or misshapen in relation to the adjacent teeth.

- The amount of bone support remaining after crown lengthening could unfavorably affect the mobility of the tooth, if it adversely affects the crown-to-root ratio. Occlusal function and parafunction are also important factors to be considered. A shortened tooth is more susceptible to mobility or fremitus and trauma from occlusion.

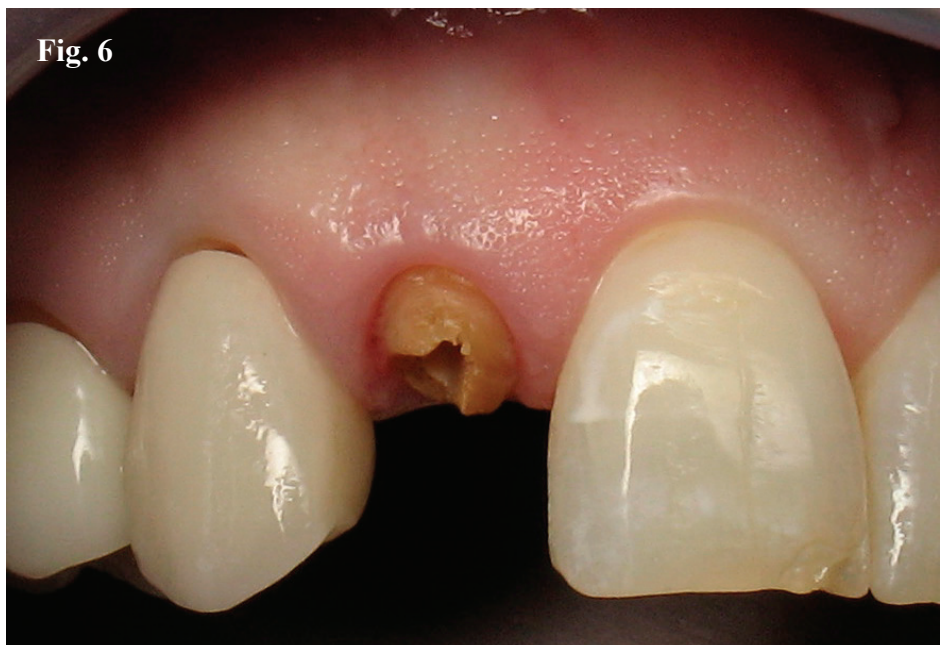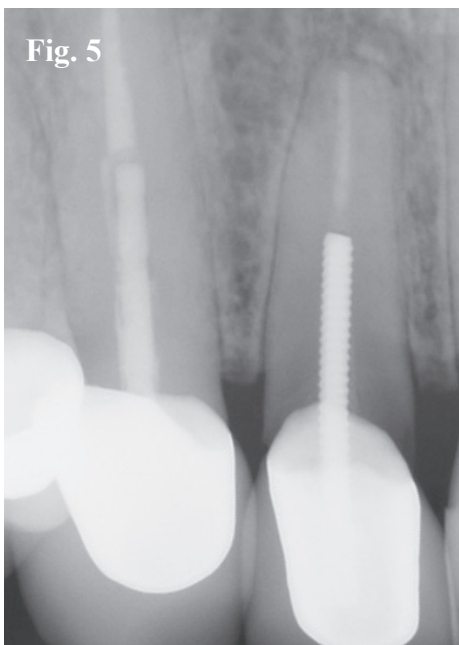


Figure 5. Radiographic evidence of severe caries on tooth #7. Figure 6. Following crown removal, minimal tooth anatomy is present for a crown preparation and retention. A decision must be made to either proceed with surgical crown lengthening or extraction and implant placement.

- Tooth anatomy must be considered when performing crown lengthening on molars and premolars to prevent exposing the furcations, especially on the buccal surfaces.
- Biomechanical risk factors must be considered if crown lengthening will affect the functional demands placed on the restored tooth. Sufficient tooth structure must remain for an adequate ferrule to support the resistance and retention of the restoration.
- Patients with greater susceptibility to decay have a poorer prognosis for the long-term retention of a structurally compromised tooth.

If one or more of the risk factors presented above compromises the longevity of the tooth, a dental implant may be preferred to crown lengthening

Crown lengthening, when appropriate, can be a conservative method of retaining a tooth when compared to extraction, bone regeneration and placing a dental implant.

Issues Related to Open Contacts

Open contacts may be the result of poorly contoured restorations, interproximal wear, occlusal factors and malposed teeth. Class II composite restorations are particularly prone to contact failure. Open contacts may lead to food impaction, gingival inflammation,

localized periodontal defects and loss of clinical attachment.

Open contacts as an etiologic factor in loss of attachment has been well documented in the periodontal literature. Slightly open contacts are prone to food impaction, while wider openings tend to contribute to food retention.

Occlusal forces, “plunger cusps,” and poorly contoured restorations are prone to open contacts. Restorations should strive to reflect natural interproximal contacts.

Dental implants adjacent to natural teeth are particularly prone to open contacts. The literature suggests an incidence of 34 to 66 percent. This may occur as early as three months after insertion and is most often found on the mesial aspect of an implant-supported crown.

Open contacts should be evaluated as part of any periodontal/restorative exam. Many practitioners will be surprised to see how many isolated posterior periodontal defects are associated with open contacts.

Implant Cementation Techniques

Residual subgingival implant cement is a major problem in implant dentistry. The literature suggests that up to 80 percent of peri-implantitis is directly related to residual implant cement.

Cement related peri-implant disease may take as much as five to seven years to manifest itself. Residual cement provides a nidus for the growth of pathogenic microorganisms. It is particularly difficult to anticipate this problem in cemented restorations because most cements are not radiopaque. A luting cement containing zinc or fluoroaluminosilicate glass (FAS glass) is preferred as it allows for visualization of the excess cement.

Numerous clinicians have discussed strategies to identify, diagnose and prevent excess cement around implant restorations. Their recommendations include:

- Use a radiopaque cement which facilitates visualization on a radiograph.
- Tapering the abutment with flutes supports the outflow of cement.
- Place a minimal rim of cement in the gingival aspect of the crown margin.
- Utilize the ‘mock abutment technique.’ This technique has been presented to minimize excess cement by using a fast setting vinyl polysiloxane custom-made duplicate abutment. Fabricating an abutment replica allows excess cement to be extruded before cementation. A die spacer may provide additional space for cement within the crown.
- Design custom abutments which limit the gingival extent of the crown to no more than 1 1/2mm subgingivally. This facilitates cement removal.

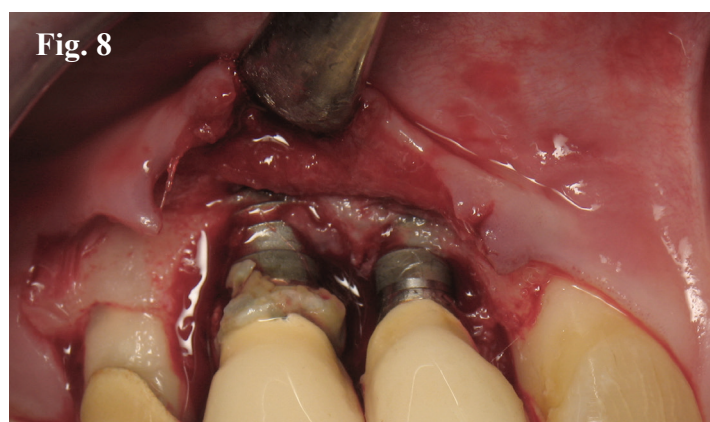
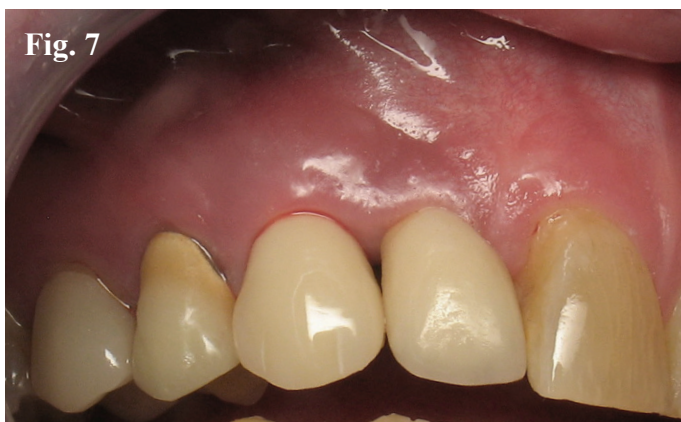

Figure 7. The peri-implant tissue on the canine exhibits spontaneous bleeding with edematous and inflamed tissue. Figure 8. Gingival flap reflection reveals excessive subgingival cement, which has caused significant bone loss around the implants on tooth numbers 6 and 7.

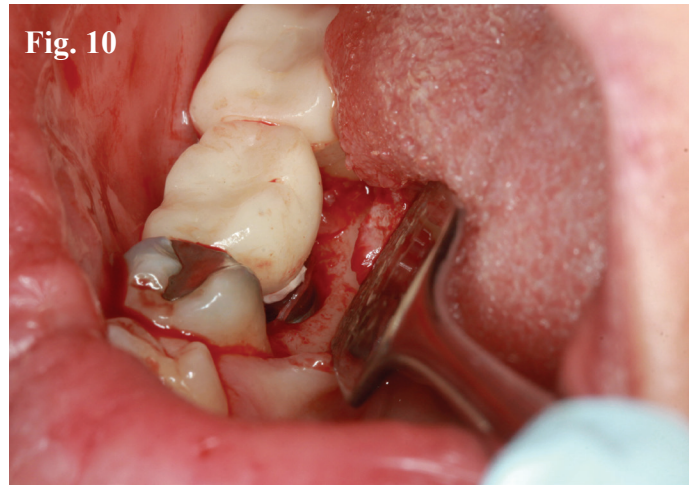
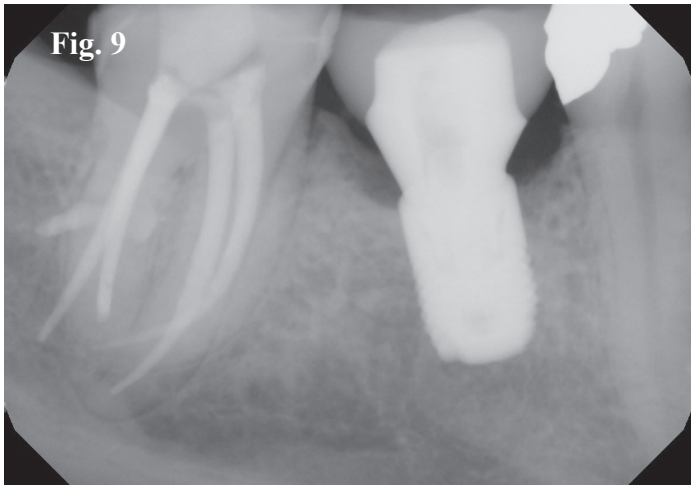

Figure 9. Radiographic evidence reveals bone loss around the implant. Figure 10. Flap reflection reveals retained subgingival cement which caused the bone loss.

The peri-implant tissues should be periodically monitored to permit early recognition of mucositis and peri-implantitis. Sulcular bleeding is a sign of mucositis. Suppuration and radiographic evidence of crestal bone loss indicates peri-implantitis. Immediate treatment should commence when these symptoms are observed.

Why Thicker Soft Tissue is Important Around Dental Implants

Thicker gingival tissues tend to protect the attachment apparatus supporting natural teeth and soft tissue adhesion around implants.

This may be because the blood supply for the attachment is derived from the overlying soft tissue.

Thick gingival tissue favors an esthetic outcome because it is less susceptible to recession and is more resistant to prosthetic manipulation.

Conversely thin scalloped gingiva is more prone to recession and compromised esthetics from metal “show through” and the development of “black triangles.” Soft tissue augmentation via autograft or

allograft may offer protection from these problems.

Tooth shape is also correlated with soft tissue morphology and esthetics. Triangular teeth are associated with a thin, scalloped periodontium, with the contact area in the coronal third often resulting in a long, thin papilla. A square anatomic crown is associated with a thick, flat periodontium. The contact area, which is in the middle third of the crown, supports a short, wide papilla.

Assessing gingival thickness as part of the pre-implant evaluation process is essential to achieving more stable and esthetic results, preventing bone loss and ensuring long term success.

In addition, it is important to recognize prior to treatment that the most difficult esthetic cases are those patients who show gingiva above the clinical crown of the tooth.

Shaping Tissue With Screw-Retained Provisionals

The ultimate goal in providing anterior dental implant restorations is to replicate the healthy natural tooth.

The shape and contour of a dental implant is quite different from a natural tooth root. Soft tissue contours are more challenging as the cervical area of an implant is conical and often much narrower than a natural tooth. Consequently soft tissue contours are more challenging with implants than they are with natural teeth.

Placing the implant in an ideal position enhances the probability of a well-contoured restoration. “Guided Implant Surgery” helps overcome many of these issues. A customized healing abutment helps to maintain the anatomic form of a natural tooth.

Screw-retained restorations are preferable to cement-retained restorations because they eliminate cement issues and permit “shaping” of the provisional restoration to develop adjacent soft tissue to more precisely reproduce the appearance of a natural tooth.

Conclusion

We hope these five concepts will be helpful to you in addressing the restorative and dental implant needs of your patients, and in choosing the most appropriate treatment with the most predictable outcome.

